

QR CODE



Frictional Keratosis of the Tongue: A Case Report

SANA KHALED¹, SATYANARAYANA DANTALA²A
B
S
T
R
A
C
T

Frictional keratosis is a reactive lesion that shows white lesion in the oral mucosa commonly associated with sharp margins of a broken tooth or ill-fitting dentures, it can be diagnosed by good history taking and good examination sometimes a biopsy should be taken and it is treated by removing the cause. It is also a common oral traumatic white lesion.

KEYWORDS: Frictional Keratosis, Tongue, Denture, White lesion

INTRODUCTION

White lesions are a group of pathological conditions affecting the oral mucosa giving clinically greyish or white lesions.^{1,2} They are commonly encountered during clinical dental practice. Although some benign physiologic entities may present as white lesions, systemic conditions, infections and malignancies may also present as white oral lesions.³ The white lesions obtain their characteristics appearance from the scattering of light through an altered mucosal surface. Such alterations may be the result of hyperkeratosis (thickened layer of keratin/increased keratin production), acanthosis (abnormal but benign thickening of stratum spinosum), intracellular edema of epithelial cells, reduced vascularity of subjacent connective tissue, surface necrosis, fibrinous exudates covering an ulcer or fungal colonies.⁴

White lesions were formerly called leukoplakia and believed often to be potentially malignant. The term leukoplakia is now restricted to white lesions of unknown cause. Most white lesions are innocuous keratoses caused by cheek biting, friction, or tobacco use, but other conditions must be excluded, usually by biopsy. These include infections (such as candidiasis, syphilis, and hairy leukoplakia), dermatoses (usually lichen planus), and neoplastic disorders (such as leukoplakias and

carcinomas). Chronic candidiasis may produce tough, adherent white patches (chronic hyperplastic candidiasis or candidal leukoplakias), which can have a malignant potential and may clinically be indistinguishable from other leukoplakias, though they may be speckled.⁵

Frictional keratosis is a reactive white lesion caused by prolonged mild irritation of the mucous membrane. It shows rough and frayed surface and upon removal of the offending agent, the lesion resolves in 2 weeks. Biopsies should be performed on these lesions that do not heal to rule out a dysplastic lesion.^{3,6,7} It is mostly caused by acute trauma which in turn causes ulcers while long standing chronic trauma causes hyperkeratosis. The etiology for frictional keratosis is habitual cheek biting, orthodontic appliance, ill-fitting denture, broken cusp, rough edges of a carious tooth or maligned teeth. Clinical features are at first a patch which is pale translucent later it becomes dense and white, mostly they occur in areas that are commonly traumatized like buccal mucosa along the occlusal line, lips, lateral margins of tongue.⁴

CASE REPORT

A 68 year old female patient, resident of Telangana reported to dental clinic with chief complaint of

broken tooth in the upper right back region of jaw and swelling on the right side of the tongue since one year. Patient complained that the swelling on the tongue increased in size over a period of one year with mild pain associated with it. Patient was diabetic since 5 years and was on medication for it. During intra-oral examination, on inspection, swelling was seen on right postero-lateral aspect of the tongue in relation to maxillary right second molar which was measuring about 5x4 cms in size, greyish white in colour having lobulated appearance (Figure. 1). On palpation, all the inspectory findings were confirmed. Swelling on the tongue was having keratotic, lobulated surface, smooth in texture, non-tender and no pus discharge was seen. Rest of the intraoral examination revealed grossly decayed maxillary right second molar with a broken cusp (Figure. 2), along with generalized chronic periodontitis.

On the basis of case history and oral examination, a provisional diagnosis of irritational fibroma on right postero-lateral aspect of the tongue was put forth with differential diagnosis of carcinoma of the tongue. To rule out any dysplastic activity of the lesion, investigatory procedures were performed i.e.; complete blood picture and random blood sugar, incisional biopsy on the right postero-lateral aspect of the tongue and orthopantomogram. Blood reports were normal and orthopantomogram revealed a large radiolucency at the periapical region and broken cusp in relation to maxillary right second molar (Figure. 3). Finally incisional biopsy was performed on right postero-lateral aspect of the tongue and a soft tissue specimen measuring of about 0.5 x 1 cms in size and greyish white in colour. Entire bit of the soft tissue was sent for Histopathological examination.

Histopathological report revealed mild hyperkeratosis with parakeratosis and acanthosis. Mild papillomatosis with mild spongiosis is also seen. Focal basal degeneration with lichenoid infiltrate is seen. No evidence of malignancy is seen (Figure. 4). A final histopathological diagnosis given was frictional keratosis of the tongue with no dysplasia. The treatment plan included patient education and motivation, along with removal of maxillary right second molar and monthly review for three months followed by quarterly review was advised.

SUMMARY

Frictional keratosis is one of the most commonly associated traumatic oral lesions which is mostly associated with chronic trauma by sharp edges of the tooth. Many of them are harmless and do not require any treatment other than reassurance from the side of the clinician. But still a small minority roughly 4% are potentially dangerous if left unattended.⁷ Following diagnostic algorithm for oral white lesions, if the lesion after monitoring for 6 weeks still persists, biopsy has to be performed and if results indicate keratosis with no dysplasia then proper follow-up and review are necessary.⁸

Early diagnosis depends upon clinician or patient who may identify a suspicious lesion or symptom while it is still at an early stage. A white or red patch should be carefully inspected for a change in size, colour, mobility, contour, texture, or function of intraoral, extra oral or perioral tissue should arouse suspicion of the presence of malignant or premalignant lesions in these regions. All medical and dental examination should include comprehensive head and neck examinations with biopsy and further investigations when indicated. Any white lesion must be considered a potentially malignant disorder until proven otherwise. General practitioners must spend more time examining their patient's thoroughly.⁹ A careful observant eye and sensible judgement can add to the diagnostic skills of the clinician and are considered important for proper patient care

REFERENCES

1. Shafers textbook of Oral Pathology- 7th edition
2. Burket LW. Oral Medicine Diagnosis and Treatment, 9th edition, J.B Lippincott Company.
3. Panat SR, Yadav N, Sangamesh NC, Aggarwal A. White lesions of oral mucosa- A diagnostic dilemma. Journal of Dental Sciences & Oral Rehabilitation 2011;2(2):8 - 10
4. Regezi J, Sciubba J, Jordan R. Oral Pathology, clinical pathologic correlations - 5th Edition. Elsevier Publishers.
5. Scully C, Porter S. ABC of oral health, Swellings and red, white, and pigmented lesions. BMJ 2000;321
6. Jayanthi P, Ranganathan K. Differential diagnosis of white lesions of oral mucosa. J Orofac Sci 2010;2(2):58-63.

7. Joshy VR, Hari S. White lesions of the oral cavity – diagnostic appraisal & management strategies. *Journal of Clinical Dentistry* 2005;1(1):27-30.
8. Lee KH, Polonowita AD. Oral white lesions: Pitfalls for diagnosis. *MJA* 2009; 190: 274-7.

9. Azzeghaib YAN. A Brief Overview of Oral Potentially Malignant Disorder. *British Journal of Medicine & Medical Research* 2015;6(1):48-55.

Source of support: Nil, **Conflict of interest:** None declared

Cite this article as:

Khaled S, Satyanarayana D. Frictional Keratosis of the Tongue: A Case Report. *Int Healthcare Res J* 2017;1(3):24-6.

AUTHOR AFFILIATIONS:

1. Consultant Oral and Maxillofacial Pathologist, Simply Smilez Dental Clinic, Hyderabad, India
2. Assistant Professor, Panineeya Dental College, Hyderabad, India

Corresponding Author:

Dr. Satyanarayana Dantala
Assistant Professor, Panineeya Dental College,
Hyderabad
satya.gullu@gmail.com

LEGENDS

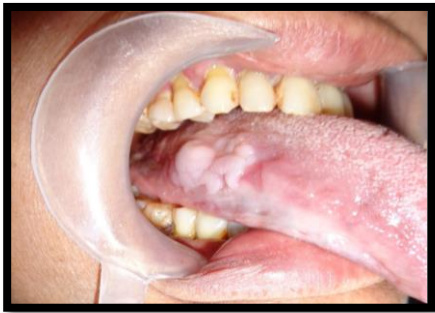

Figure 1. Swelling on the tongue

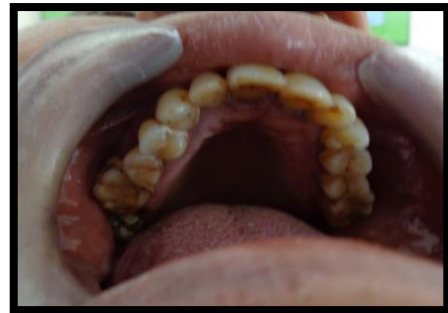

Figure 2. Grossly decayed maxillary molar

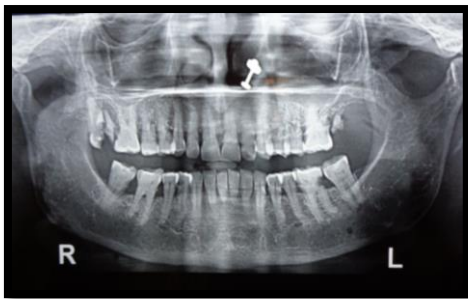


Figure 3. Orthopantomogram revealed a large radiolucency at the periapical region and broken cusp in relation to maxillary right second molar

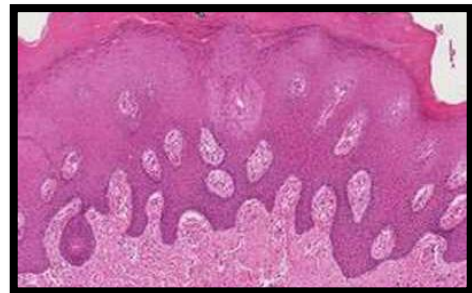

Figure 4. Histopathological changes