

QR CODE



Intentional Replantation: A Last Resort for Treatment of Periodontally Hopeless Teeth

SANTOSH CHHATTANI*¹, ROSHANI THAKUR², MOTILAL JANGID³, NEELU KASARE⁴A
B
S
T
R
A
C
T

Periodontal disease is an inflammatory response to the bacterial biofilm which leads to inflammation of periodontal structures and further results in loss of attachment and bone loss which in severe cases leads to mobility of teeth, eventually may cause exfoliation of teeth. Treatment option for excessive mobile teeth is extraction and replacement can be carried out with fixed partial denture or implant placement. In patients with financial constraints and also the patients in whom the fixed partial denture is contraindicated, intentional replantation of periodontally hopeless teeth is an alternative treatment modality. It's a procedure of purposely removing a tooth and replacing it in a more apical position. Thus, this procedure of intentional replantation can be considered as an alternative treatment modality rather than extraction of periodontally hopeless teeth.

KEYWORDS: Periodontally Compromised, Replantation, Platelet Rich Fibrin

INTRODUCTION

The periodontal therapy in teeth with advanced bone loss, a significant grade of mobility, tooth migration and elongation; often exposes the dental clinician to a challenging decision when it comes to the effective treatment for the patient.¹ There are various functional problems in the treatment of anterior teeth with periodontal destruction. The treatment of choice for periodontally involved hopeless teeth is usually extraction.²

However, in cases where extrusive luxation is severe and the tooth is highly mobile, extraction is the recommended procedure and replacement of the missing teeth may be done using removable partial denture (RPD), fixed partial denture (FPD) or implant placement. Intentional replantation may be considered as an alternative treatment option in patients who are unable to afford the treatment cost of implants or in cases where FPD is contraindicated.³ Intentional replantation is described as an intervention to purposely remove a tooth and to replace it in its socket following certain extra-oral procedures. Improving the support of periodontal tissue and thereby increasing the survival and functional quality of replanted teeth remains a major concern in cases of periodontally hopeless teeth. In order to enhance the outcomes obtained with intentional reimplantation, supportive treatments have been proposed.⁴

According to many authors, intentional reimplantation is considered as a last resort for

preserving an otherwise missing tooth. Even though intentional reimplantation is contraindicated in periodontally involved teeth in which there is significant mobility of tooth, furcation involvement or inflammation of gingiva, some authors have reported good results after reimplantation of teeth with periodontal involvement.^{5,6}

CASE REPORT

A 35-year-old male patient reported to the Department of Periodontics and Oral Implantology with a chief complaint of increasing gap in between upper front teeth since 8 months giving a bad appearance in the esthetic zone. On clinical examination, pathologically migrated 11,12,21,22 and grade II mobility with 11 was noticed. On probing, pocket depth was 9 mm on the mesial aspect of 11 and 4 mm in the distal and palatal aspect (figure 1). Radiographic examination revealed moderate to severe bone loss in relation to 11.

1. Treatment plan: Patient being middle aged, requested to retain his natural tooth and denied for extraction of the tooth for esthetic concern and also due to financial reasons. Considering the clinical condition, intentional replantation of 11 was scheduled after explaining the advantages and disadvantages of the procedure to the patient. Following the completion of phase I therapy, intentional root canal treatment was done in relation to 11. The reimplantation procedure was planned four weeks after the completion of root canal



© Santosh Chhattani et al. This is an open access article distributed under the terms of the Creative Commons Attribution License CC-BY-NC 4.0, which permits unrestricted use, distribution and reproduction in any medium, provided the use is not commercial and the original author(s) and source are cited.

treatment.

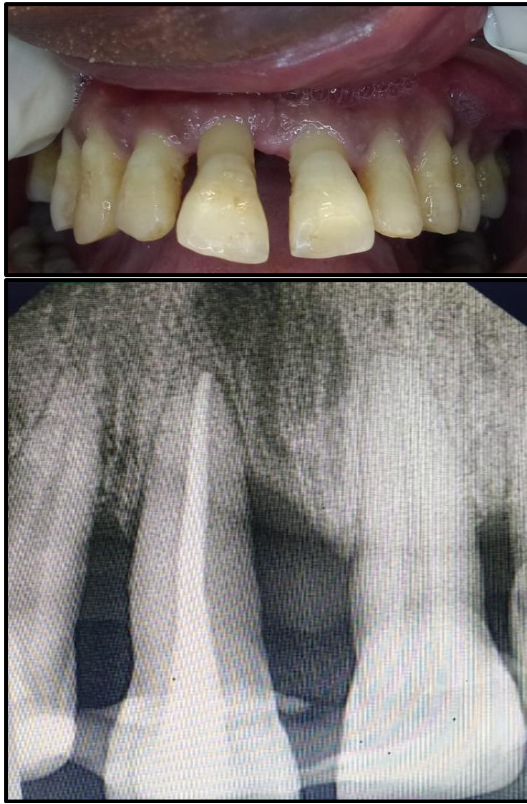

Figure 1. Preoperative clinical picture and IOPA

2. Surgical procedure: Extraoral scrub with betadine was applied after which local anesthesia (2% lignocaine HCl with 1:80000 adrenaline) was administered to anaesthetize the surgical area. Tooth was atraumatically extracted (figure 2). Extracted tooth was carefully root planed for removal of necrotic cementum and granulation tissue. It was then placed in a solution of tetracycline (500 mg of tetracycline dissolved in 20 ml saline) for a period of 5 minutes (figure 3).

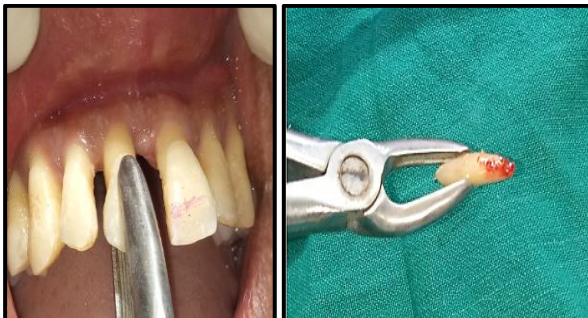


Figure 2. Atraumatically extracted tooth

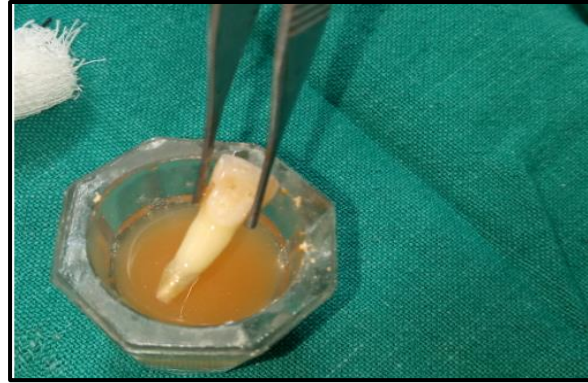

Figure 3. Tooth placed in tetracycline solution

A total volume of 10 ml blood was withdrawn, which was immediately centrifuged at 3000 rpm for 10 minutes for the preparation of Platelet Rich Fibrin (PRF) following the protocol as recommended by Dohan DM et al.⁷ (figure 4).

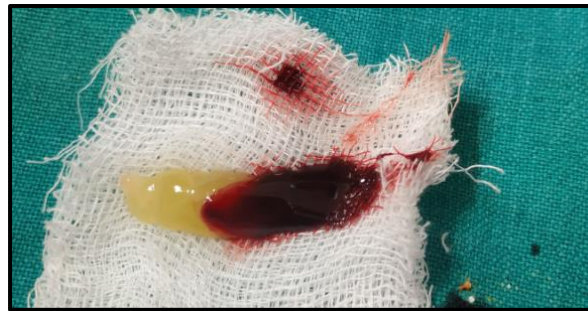

Figure 4. Platelet rich fibrin

Using implant drills, the socket was extended apical to its base, with sequential drills till the tooth completely fits into the new socket (figure 5).

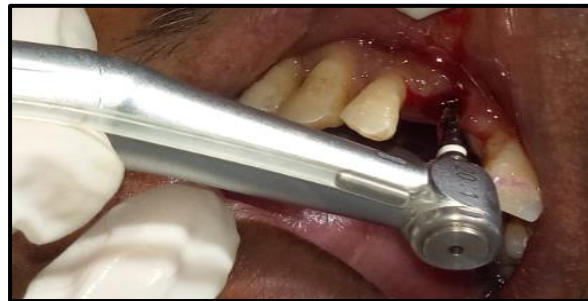

Figure 5. Reimplantation site preparation

PRF obtained was placed in the tooth socket and tooth was reinserted in the extraction socket with an attempt to realign it (figure 6).

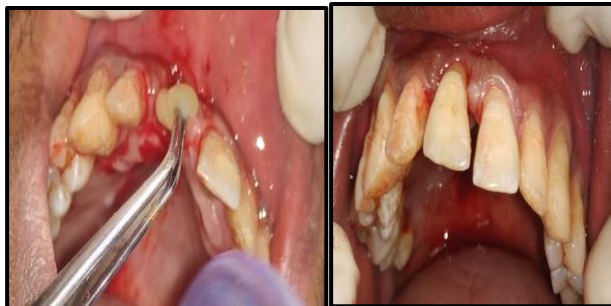

Figure 6. Placement of PRF and tooth reinserted in the extraction socket

Tooth was splinted with the ligature wire and flowable composite. Splinting was retained for 3 months [figure 7(a)]. Post-operative medications were prescribed that included antibiotics and an analgesic for 5 days. 0.2% chlorhexidine mouthwash was prescribed for 14 days starting from the day following surgery. Post operative instructions were given to the patient to maintain proper oral hygiene. Post operative intra oral radiograph of 11 was taken immediately [figure 7(b)]. Patient was recalled for check-up every week for a month and every 4 weeks then after [figure 8 (a) & (b)].

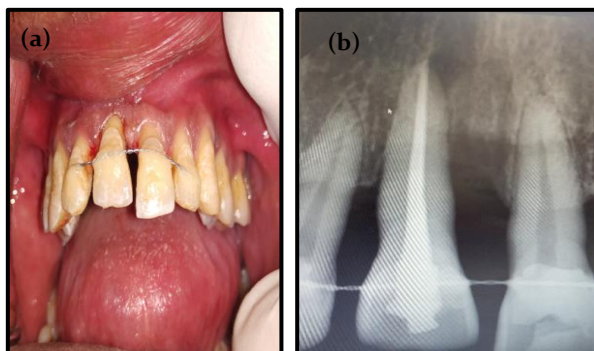


Figure 7 (a). Splinting done and tooth stabilized
Figure 7 (b). Immediate post-operative IOPA

Patient is still under continued supportive periodontal therapy and has not shown any untoward effects of root resorption or mobility.

DISCUSSION

Intentional replantation is often considered as one of the last treatment option for periodontally hopeless teeth.

Some authors have also reported successful results. Baykara and Eratalay (1995) carried out intentional

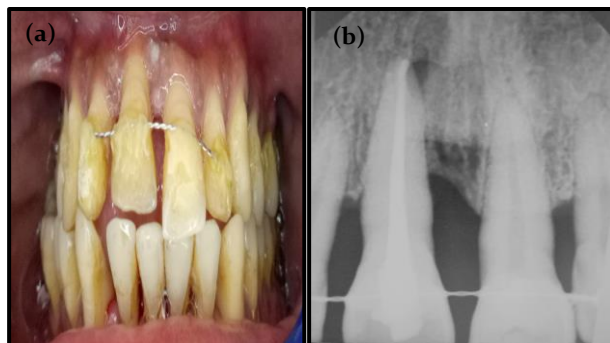


Figure 8 (a). 3 months follow-up
Figure 8 (b). 3 months post-operative: Shows definitive radiopacity in periapical area

replantation of teeth with periodontal involvement and reported successful outcomes for a period of 8 years.⁸ Demiralp et al. (2003) reimplanted periodontally hopeless teeth and obtained good outcomes at 6 months.² Yaprak et al.(2010) performed intentional reimplantation of two maxillary central incisors which were highly mobile due to advanced periodontal involvement and obtained successful results on 4 year follow up.⁹

In the present case, a similar treatment plan was formulated. The present case was followed up for a period of 3 months and is still under continuous follow up. Another option for this procedure could be extraction of central incisor and replacement with a fixed prosthetic including laterals and opposite central. However, this treatment option would be concluded with some outcomes and little expensive treatment alternative for the patient.⁵

In the present case, patient was middle aged and had financial constraints for fixed partial denture or implant therapy. He was willing to save the natural tooth in spite of the informed risks and chances of treatment failure.

The tooth had high grade of mobility in the present case and therefore, the exposed portion of the root would have been devoid of essential PDL cells that can serve as a nidus for infection and thus contribute to external root resorption.

Tetracycline solution is considered to have antibacterial, anti-inflammatory as well as anti-collagenase property and therefore, the tooth was treated with this solution. Studies have reported good outcomes in bone gain and in reduction of

probing pocket depth at the end of 6 months when intentional replantation of periodontally hopeless teeth was performed after treating with tetracycline-HCl.¹⁰

In the present case, a substantial improvement in bone support and reduction in the mobility of tooth has been observed following reimplantation. These findings can be compared to the study done by Demir et al. They carried out intentional reimplantation with PRP, bioactive glass graft material and non-resorbable polytetrafluoroethylene membrane in periodontally hopeless teeth with grade II mobility and obtained a substantial bone formation and reduction in mobility on 12 month follow up.¹⁰

In our case, the bone fill and healing was improved by the advantages of sustained release growth factors that could have contributed to the success of the treatment.

In the present case, prosthetic replacement was not considered due to the financial limitations of the patient.

CONCLUSION

For the tooth with a hopeless prognosis and extensive mobility intentional reimplantation is an alternative treatment. This procedure is relatively conservative and affordable when compared to other treatment modalities used for replacing missing teeth. Therefore, further research and long-term follow-up are required to establish this modality of treatment. The outcome of the case shows increase in longevity of the tooth.

REFERENCES

1. Solakoglu Ö, Filippi A. Transreplantation: An alternative for periodontally hopeless teeth. *Quintessenz Int.* 2017;48:287-93. <https://doi.org/10.3290/j.qi.a37806>
2. Demiralp B, Nohutçu RM, Tepe DI, Eratalay K. Intentional replantation for periodontally involved hopeless teeth. *Dental Traumatology* 2003 Feb;19(1):45-51.
3. Patel GK, Gujjari SK, Annapoorna BM, Kumar SV. Management of chronic luxated central incisor with hopeless prognosis. *Journal of Indian Society of Periodontology* 2013;17(5):670.
4. Keceli HG, Hendek MK. Fifteen months follow-up of a hopeless tooth treated with two-step procedure involving intentional replantation and free gingival graft. *European Journal of Dentistry* 2014;8(4):559.
5. Nagappa G, Aspalli S, Devanoorkar A, Shetty S, Parab P. Intentional replantation of periodontally compromised hopeless tooth. *Journal of Indian Society of Periodontology.* 2013;17(5):665.
6. Elgendy EA, Shoukheba MY, Abo-Shady T, El Fahl BN. Re-implantation of hopeless tooth due to periodontal disease by using implant surgical drilling: Case report study. *Tanta Dental Journal* 2013;10(3):112-5.
7. Dohan DM, Choukroun J, Diss A, Dohan SL, Dohan AJ, Mouhyi J et al. Platelet-rich fibrin (PRF): a second-generation platelet concentrate. Part II: platelet-related biologic features. *Oral Surg Oral Med Oral Pathol Oral Radiol Endod.* 2006;101(3):e45-50. <https://doi.org/10.1016/j.tripleo.2005.07.009>.
8. Baykara M, Eratalay K. Replantation in cases with advanced periodontal destruction. *J Hacettepe Fac Dent.* 1995;19:124-8.
9. Yaprak E, Hakk SS, Akman S, Belli S. Aesthetical and functional management of periodontally involved hopeless anterior teeth with multidisciplinary approach: 4 years follow-up. *SU Dishek Fak Derg.* 2010;19:176e81.
10. Demir B, Demiralp B, Güncü GN, Özgür Uyanık M, Çağlayan F. Intentional replantation of a hopeless tooth with the combination of platelet rich plasma, bioactive glass graft material and non-resorbable membrane: a case report. *Dental Traumatology* 2007;23(3):190-4.

Cite this article as:

Chhattani S, Thakur R, Jangid M, Kasare N. Intentional Replantation: A Last Resort for Treatment of Periodontally Hopeless Teeth. *Int Healthc Res J.* 2021;4(11):CR1-CR5. <https://doi.org/10.26440/IHRJ/0411.02386>

Source of support: Nil, **Conflict of interest:** None declared

AUTHOR AFFILIATIONS: (*: Corresponding Author)

1. Final Year Post Graduate Student
2. Professor and HOD
3. Reader
4. Second Year Post Graduate Student
Department of Periodontology, Saraswati Dhanwantari Dental College, Parbhani, Maharashtra

Contact Corresponding Author at: [sc901121166\[at\]gmail\[dot\]com](mailto:sc901121166@gmail.com)