



Prevalence of Haller's Cells in OPG and Its Clinical Correlation: A Retrospective Study

ANURADHA YADAV¹, UPASNA SETHI AHUJA², ACHINT GARG³, KESARI SINGH⁴

A
B
S
T
R
A
C
T

INTRODUCTION: Haller's cells arise with the pneumatization of the lateral crus. Although Haller's cells are anatomical variations in the development of the nose and paranasal sinuses, they are found responsible for the patient's symptoms and are thus clinically significant.

AIM: The purpose of the present study is to emphasize the appearance of Haller's cells on panoramic radiographs and their clinical correlation.

MATERIALS AND METHOD: OPG scans of 700 subjects of either gender in the age range of 16 to 60 years were evaluated for the presence of Haller's cells and retrospectively patient's clinical features were seen. Gender, age, and clinical relevance were observed. A Chi-square test was used to evaluate the prevalence of Haller's cell in panoramic radiograph (OPG), its occurrence in males and females, and its clinical correlation. The software used for statistical analysis was SPSS version 21.0 and the p-value, of less than 0.05 was considered significant.

RESULTS: Haller's cells were detected in 95 scans of 700 OPGs, the overall prevalence of Haller's cells was 13.5 % with an overall p-value less than 0.05 rendering it significant. Of the 95 cases with Haller's cells, 55 (57.89%) were in males and 40 (42.10%) were found in females. The p-value was 0.32 (> 0.05) rendering it non-significant.

CONCLUSION: . More prospective analysis with thorough medical history and examination, with the larger group of the population, might further confirm the appearance of Haller's cells on panoramic radiographs.

KEYWORDS: Haller's cells, Radiograph, Panoramic

INTRODUCTION

Infraorbital ethmoid cells are extensions of the anterior ethmoid sinus into the floor of the orbit and superior aspect of the maxillary sinus. This entity is also known as Haller's cell, named after anatomist Albrecht von Haller, who in 1765 had described this ethmoidal pneumatization of the floor of the orbit, also named as orbitoethmoidal cells or maxillo-ethmoidal cells. However, the name infraorbital ethmoid cell is recommended because it describes the location and origin of the entity.^{1,2} Infraorbital ethmoid cells have been described as well-defined, round, oval, or teardrop-shaped radiolucencies (single or multiple), unilocular or multilocular with a smooth border that may or may not appear corticated, and are located medial to the infraorbital foramen according to a solitary panoramic radiographic study.³

In addition to distressing oro-facial pain and sinusitis, numerous pathologies and symptoms associated with this entity include nasal obstruction, impaired nasal breathing, headache, chronic cough, and mucocoeles.^{1,3,4} Haller's cells can also restrict access to the maxillary sinus or the anterior ethmoidal cells during endonasal

procedures, making it imperative for the surgeon to be aware of such variations that may incline the patient to increased risk of intraoperative complications.^{1,5}

Haller's cells are usually detected radiologically as they cannot be seen during a normal nasal endoscopy, except one performs in addition to maxillary sinusoscopy. They may not only contribute to the development of maxillary sinusitis by narrowing the natural sinus ostium but they can also be diseased themselves as well.

CT is commonly used for imaging infraorbital ethmoid cells⁶, although maxillary sinus endoscopy⁴ may also reveal this structure. Panoramic radiographs often show Haller's cells and as a dental professional panoramic radiograph is the basic radiographic investigation that we can perform for screening purposes. Therefore, panoramic radiographs can be used to identify these anatomic variations avoiding other imaging modalities which are rather expensive, involve higher patient radiation exposure, and are invasive.



© Anuradha Yadav et al. This is an open access article distributed under the terms of the Creative Commons Attribution License CC-BY-NC 4.0, which permits unrestricted use, distribution and reproduction in any medium, provided the use is not commercial and the original author(s) and source are cited.

Submitted on: 30-Dec-2021; Accepted on: 17-Apr-2022

MATERIALS AND METHOD

Panoramic radiographs of dental outpatients visiting the Department of Oral Medicine and Radiology, I.T.S Dental College And Hospital, Greater Noida, U.P. The study group comprised 700 subjects of either gender in the age range of 16 to 60 years selected by simple random sampling. OPGs with normal dentition and bone trabecular patterns were selected and the Exclusion criteria were OPGs with an altered trabecular pattern suggestive of systemic diseases which had/have affected the growth. OPGs with clinical or radiographic evidence of developmental anomalies of the maxillofacial region. OPGs with clinical or radiographic evidence of bony pathologies involving the maxillofacial region. OPGs with clinical or radiographic evidence of fractures of the oral and maxillofacial region and/or treatment received for the same. OPGs with the clinical or radiographic evidence of tumors/cysts of the odontogenic region.

Ethical clearance was obtained from the institution prior to conducting the study. Digital Panoramic radiographs were obtained from Planmeca Proline XC panoramic X-rays unit. Analysis of the same was done with the Planmeca Romexis imaging software on LED screens.

Retrospectively digital panoramic radiographs which falls within the criteria mentioned in the study were selected and viewed. The presence of Haller's cells on the panoramic radiograph was carefully studied on screens of LCD monitors.

The identification of the same was made if an anatomic variation fulfilled all of the following criteria as suggested by Ahmad et al.³:

1. Well-defined round, oval, or tear-drop-shaped radiolucency, single or multiple, unilocular or multilocular, with a smooth border, which may or may not appear corticated.
2. Located medially to the infraorbital foramen.
3. All or most of the border of the entity in the panoramic section is visible.
4. The inferior border of the orbit lacks cortication or remains indistinguishable in areas superimposed by this entity.

The data collected were tabulated and subjected to statistical analysis namely Frequencies/percentages, Descriptive Statistics, Chi-square test, and Cross

tabulation (contingency table analysis) using SPSS for windows to obtain the results.

RESULTS

The study group comprised of 700 subjects of either gender in the age range of 16 to 60 years, from the outpatients visiting the Department of Oral Medicine and Radiology, I.T.S. Dental College and Hospital, Greater Noida.

The data were tabulated and subjected to statistical analysis. The results obtained and the observations are as follows: Overall Distribution of Study subjects with respect to gender was like the total sample size of the study was 700, consisting of 455 males and 245 females, with male to the female ratio being 1.8:1. (figure 1)

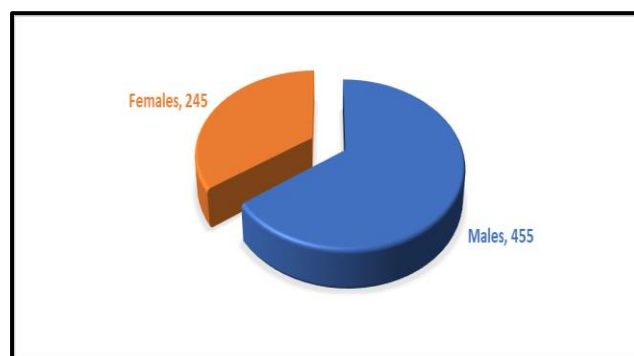


Figure 1. Overall distribution of study subjects with respect to gender

Of the 700 study subjects, Haller's cells were found in 96 subjects. The overall prevalence of Haller's cells was 13.5 % and the p-value was found to be 0.00 (< 0.05) which is significant. (Table 1)

| | Frequency | Percentage |
|---------|-----------|------------|
| Absent | 605 | 84.0 |
| Present | 95 | 13.5 |
| Total | 700 | 100 |

Chi sq = 277.4 , degree of freedom = 2 , p = 0.00 (< 0.05)

Table 1. Overall distribution of study subjects with respect to gender

Of the 95 cases with Haller's cells, 55 (57.89%) were in males and 40 (42.10%) were found in females. The p-value was 0.32 (> 0.05) rendering it non-significant,

which was consistent with the findings of Solanki. J et al.⁷ (Table. 2)

| GENDER | Haller's cells present | | Total |
|---|------------------------|---------------|--------------|
| | Absent | Present | |
| Male Count % within sex | 400 66.2% | 55 57.89% | 455 63.8% |
| Female Count % within sex | 205 33.8 % | 40 42.10 % | 245 36.2% |
| Total Count % within sex | 605 100 % | 95 100 % | 700 100% |
| Contingency coefficient value 0.040, P = 0.320 (> 0.05) | | | |

Table 2. Overall distribution of Haller's cells with respect to gender

Out of 95 cases of Haller's cells, only 18 (18.94%) gave a positive history of clinical disease whereas 77 (81.05%) were asymptomatic. The p-value was 0.366 and was found non-significant (Table 3).

| | | |
|-------------------------------|----|--------|
| Presence of Clinical Symptoms | 18 | 18.94% |
| Absence of Clinical Symptoms | 77 | 81.05% |
| Total | 95 | 100% |

Table 3. Correlation of Clinical symptoms and Haller's Cells

Among 65 cases that gave a positive history of clinical diseases only 18 (27.69%) showed the presence of Haller's cells whereas in 47 (72.30%) Haller's cells were absent (Table 4).

| | | |
|----------------------------|----|--------|
| Presence of Haller's Cells | 18 | 27.69% |
| Absence of Haller's Cells | 47 | 72.30% |
| Total | 65 | 100% |

Table 4. Presence or absence of Haller's Cells

DISCUSSION

Previous studies using panoramic radiographs, done by

Ahmad et al.³ in 2006 showed 38.2 %, Raina et al.⁸ in 2012 showed 16%, Khayam et al.⁹ in 2013 showed 32.5% and Solanki et al.⁷ in 2014 was 19.2%. The overall prevalence in our study was only 13.5% which was very less. This variation can be due to different groups of the population.

Out of 95 cases of Haller's cells, only 18 (18.94%) gave a positive history of clinical disease whereas 77 (81.05%) were asymptomatic, the p-value was non-significant. Alkire and Bhattacharyya¹⁰ evaluated the effects of septum deviation, conchae bullusa, and Haller's cells on the occurrence of acute rhinosinusitis, and their results showed that just obstruction caused by Haller's cells can lead to the disease. Also, are view article reported the headache related to Haller's cells, and also has been said that Haller cells may also cause sinus disease such as mucocoele. Sebrechts et al.¹¹ acknowledged Haller cell inflammation can be as a potential reason for orbital unilateral edema and can be the main reason for it.

On the other hand, some studies suggested that the presence of Haller's cells automatically doesn't predispose an individual to sinus disease.^{2,12,13,14} In our study, 65 cases reported the presence of clinical symptoms like chronic orofacial pain, chronic headache, chronic rhinitis, and chronic sinusitis but among these only 18 (27.69%) cases showed the prevalence of Haller's cells whereas in 47 cases (72.30%) it was absent.

The present study was unique as the prevalence of Haller's cells on panoramic imaging was correlated retrospectively with the clinical case history data. The prevalence was low, which can be attributed to a different group of the population and different methods of scanning OPG than previous studies on OPG. Large variation between the prevalence of Haller's cells on CT and Panoramic images can be attributed to the specific criteria which were followed³ and also it is 3-dimensional imaging with more specification.

CONCLUSION

Though in literature the appearance of Haller's cells has been associated with some type of chronic inflammation of the osteo-meatal complex but result obtained in this study was non-significant. More prospective analysis with thorough medical history and examination, with the larger group of the population, might further show a clear picture.

REFERENCES

1. Kantarci M, Karasen RM, Alper F, Onbas O, Okur A, Karaman A. Remarkable anatomic variations in paranasal sinus region and their clinical importance. *Eur J Radiol.* 2004;50(3):296-302. <https://doi.org/10.1016/j.ejrad.2003.08.012>.
2. Yanagisawa E, Citardi MJ. Endoscopic view of the infraorbital ethmoid cell (Haller cell). *Ear Nose Throat J.* 1996;75:406-7.
3. Ahmad M, Khurana N, Jaber J, Sampair C, Kuba RK. Prevalence of infraorbital ethmoid (Haller's cells) on panoramic radiographs. *Oral Surg Oral Med Oral Pathol Oral Radiol Oral Endod.* 2006;101:658-61.
4. Yanagisawa E, Marotta JC, Yanagisawa K. Endoscopic view of a mucocele in an infraorbital ethmoid cell (Haller cell). *Ear Nose Throat J.* 2001;80:364-8.
5. Lang J. Paranasal sinuses. In: Lang J, editor. *Clinical Anatomy of the Nose, Nasal Cavity and Paranasal Sinuses.* New York: Thieme, 1989; pp. 88-9.
6. Basic N, Basic V, Jukic T, Basic M, Jelic M, Hat J. Computed tomographic imaging to determine the frequency of anatomical variations in pneumatization of the ethmoid bone. *Eur Arch Otorhinolaryngol.* 1999;256:69-71.
7. Solanki J, Gupta S, Patil N, Kulkarni VV, Singh M, Laller S. Prevalence of Haller's Cells: A Panoramic Radiographic Study. *J Clin Diagn Res.* 2014;8(9):RC01-4. <https://doi.org/10.7860/JCDR/2014/10334.4894>.
8. Raina A, Guledgud MV, Patil K. Infraorbital ethmoid (Haller's) cells: a panoramic radiographic study. *Dentomaxillofac Radiol.* 2012;41(4):305-8. <https://doi.org/10.1259/dmfr/22999207>.
9. Khayam E, Mahabadi AM, Ezoddini F, Golestani MA, Hamzeheil Z, Moeini M, et al. The prevalence of ethmoidal infraorbital cells in panoramic radiography. *American Journal of Research Communication* 2013; 1(2):109-18
10. Alkire BC, Bhattacharyya N. An assessment of sinonasal anatomic variants potentially associated with recurrent acute rhinosinusitis. *Laryngoscope.* 2010 Mar;120(3):631-4. <https://doi.org/10.1002/lary.20804>.
11. Sebrechts H, Vlamincck S, Casselman J. Orbital edema resulting from Haller's cell pathology: 3 case reports and review of the literature. *Acta Otorhinolaryngol Belg.* 2000;54(1):39-43.
12. Zinreich SJ, Kennedy DW, Rosenbaum AE, Gayler BW, Kumar AJ, Stammberger H. Paranasal sinuses: CT imaging requirements for endoscopic surgery. *Radiology* 1987; 163:769-75.
13. Earnwaker J. Anatomic variants in sinonasal CT. *Radiographics* 1993;13:381-415.
14. Lloyd GAS. CT of the paranasal sinuses: a study of a control series in relation to endoscopic sinus surgery. *J Laryngol Otol.* 1990;104:477-81.

Cite this article as:

Yadav A, Ahuja US, Garg A, Singh K. Prevalence of Haller's Cells in OPG and Its Clinical Correlation: A Retrospective Study. *Int Healthc Res J.* 2022;6(1):OR1-OR5. <https://doi.org/10.26440/IHRJ/0601.04514>

AUTHOR AFFILIATIONS: (*Corresponding Author)

1. Senior Lecturer, Department Of Oral Medicine and Radiology, I.T.S C.D.S.R., Muradnagar, Ghaziabad, India
2. Professor and Head of the Department, Oral Medicine and Radiology, I.T.S C.D.S.R., Muradnagar, Ghaziabad, India
3. B.D.S, M.S (London), FDSRC (UK), Oral Oncologist, Gurgaon, Haryana, India
4. Ex-Senior Resident Department of Dentistry, UCMS, and G.T.B., Hospital, Govt. of NCT, Dilshad Garden, New Delhi, India

Source of support: Nil, **Conflict of interest:** None declared

Contact Corresponding Author At: [annuudentalcareon\[at\]gmail\[dot\]com](mailto:annuudentalcareon[at]gmail[dot]com)