



Verrucopapillary Lesions of the Oral Cavity: A Review

SANA KHALED¹, SANTOSH R. BHARADWAJ², BUSHRA ANJUM³, D. SATYANARAYANA^{*4}

A
B
S
T
R
A
C
T

Verrucopapillary lesions are a spectrum of benign, potentially malignant and malignant lesions of the oral mucosa which usually are misdiagnosed. They pose a great diagnostic challenge mainly due to confusing terminology and also due to similar clinical and histopathological features which often makes these lesions indistinguishable from one another. The human papilloma virus (HPV) plays an important role in the pathogenesis of majority of these lesions. This review aims to summarize and highlight the key clinical and histopathological features of these lesions, and also provides a diagnostic approach to these entities.

KEYWORDS: Human Papilloma Virus (HPV), Oral mucosa, Malignancy

INTRODUCTION

Most of the biopsied lesions of the oral mucosa have shown a unique proliferation of the stratified squamous epithelium, with or without inductive changes of the underlying stroma. These proliferations fall into three types: papillary exophytic masses, broad verruciform excesses of surface keratin and flat hyperplasias of spinous cell layer. The exophytic lesions represent as any pathologic growth that projects above the normal contours of the oral surface. The papillary lesions represent swelling with finger like projections imparting a cauliflower like appearance, these micro projections are rounded and blunt like fungiform papillae of the tongue. The verrucous lesions are similar to papillary lesions yet possess a more irregular surface. These papillary or verrucous type lesions are quite common in the oral and paraoral regions, representing 3% of biopsied oral lesions. Clinical information and an adequate biopsy are essential for making an accurate diagnosis of these lesions, but the primary objective must be to evaluate the epithelium for dysplastic features and signs of invasion. Hence, differentiation between verrucous and papillary lesion is based more on microscopic features rather than the clinical appearance. Biopsy is usually indicated to secure a definitive diagnosis and to follow a proper treatment plan.

PATHOGENESIS

Majority of verrucous lesions are thought to be induced by viral infection of the epithelium especially Human Papilloma Virus (HPV). Human papilloma

viruses are a group of genetically related organisms that infect stratified squamous epithelium. There are more than 120 genetically different, yet closely related HPVs that are referred to as genotypes. Most of the oral and labial papillary lesions are HPV-associated and few are self-limited benign growths that do not progress to cancer, like keratoacanthoma.¹

GENOTYPE	LESIONS
HPV 2, 4	Verruca Vulgaris
HPV 6, 11	Condyloma Acuminatum, Squamous Papilloma
HPV 13, 32	Focal epithelial hyperplasia
HPV 16	Proliferative Verrucous Leukoplakia Subtypes
HPV 6, 11, 16	Verrucous Carcinoma
HPV 16, 18	Squamous Cell Carcinoma

Table 1. Human Papilloma Viruses and Head and Neck lesions¹

HPV EFFECTS ON ORAL EPITHELIA

The HPVs induce proliferative changes in oral epithelial cells that result in both benign and malignant tumors and can only infect parabasal or basal cells of the epithelium. Infection may be initiated by micro abrasions on the surface, which



© Sana Khaled et al. This is an open access article distributed under the terms of the Creative Commons Attribution License CC-BY-NC 4.0, which permits unrestricted use, distribution and reproduction in any medium, provided the use is not commercial and the original author(s) and source are cited.

allows better access for this virus into the basal cells. When the virus initially enters host basal cells, it cannot replicate until the cell matures into a keratinocyte, as the host cell undergoes the normal differentiation, the virus also starts its replication. The virus starts its replication once the host cell mitosis occurs. Then virus expresses its the early proteins--E1, E2, E5, E6, and E7--in the lower spinous layers which occurs in the early phases of the infection. As the epithelial cells mature, the cell cycle is halted as part of forming a protective barrier; however, terminal differentiation is hindered by E7 and E6. This has most likely evolved to allow the host cell to continue to reproduce viruses.

As the host cell life progresses to the upper spinous layer, gene expression of HPV changes. The late proteins--L1 and L2--and E4 are upregulated and at this point, virus assembly occurs and exfoliating cells of the epithelium now releases complete virions. These cells are resilient in dry environments and virions shed from cornified squames have a higher chance of survival. Cornified squames are the epithelial cells that have more keratin which is a protective agent that hardens the cell. HPV then adheres to a specific receptor protein on the keratinocytes membrane in order to be assimilated into the cell by a process known as endocytosis. Once the virus enters into the cell, it divests itself of its protein coat and the viral DNA and then utilizes host cell DNA building blocks to replicate.

These viruses elaborate early gene proteins that are able to regulate the host cell cycle or mitotic capabilities. E6 and E7 proteins are the most important in this respect, as they bind to the host proteins that are regulators of the keratinocytes cell division cycle. E6 binds to a protein designated p53, a molecule that arrest cell division, however once bound, it is degraded and this causes inhibition of keratinocytes mitosis to be nullified. Likewise, E7 binds a protein termed Rb; and it leads to cell cycle regulation disruption.²

E1 – Viral replication

E2 – Regulates viral transcription and replication

E4 – Interacts with cytoskeletal proteins

E5 – Downregulation of MHC Class 1 molecules

E6 – Oncoprotein, binds to tumor suppressor protein P53

E7 – Oncoprotein, binds to tumor suppressor protein retinoblastoma (Rb)

L1 – Major viral caspid protein

L2 – Minor viral caspid protein

ANATOMICAL LANDMARKS RESEMBLING VERRUCOUS-PAPILLARY LESIONS

Some of the normal anatomic structures in the oral cavity, presenting as a papillary pattern are accessory tonsillar tissue, filiform papillae, fungiform papillae, foliate papillae, circumvallate papillae, retrocuspid, retromolar papillae and stensens's papillae. Sometimes, these structures attain such a size that they are mistaken for pathoses. The anatomic locations of the structures, however, usually enable immediate recognition.³

CLASSIFICATIONS OF VERRUCOUS-PAPILLARY LESIONS

(A) According to Regezi JA et al, Verrucous lesions of the oral cavity are classified into:⁴

I. Reactive/Infectious Lesions

- Squamous papilloma/Oral Wart
- Inflammatory Papillary Hyperplasia
- Condyloma Acuminatum
- Condyloma Latum
- Focal Epithelial Hyperplasia (Heck's Disease)
- Molluscum Contagiosum

II. Neoplasms & Pre-malignant Lesions

- Keratoacanthoma
- Giant Cell Fibroma
- Verrucous Hyperplasia
- Proliferative Verrucous Leukoplakia
- Verrucous Carcinoma
- Papillary squamous Cell Carcinoma
- Sialadenoma Papilliferum

III. Idiopathic/Miscellaneous Lesions

- Pyostomatitis Vegetans
- Verruciform Xanthoma
- Dariers Disease
- Warty Dyskeratoma

(B) According to Gareth J Thomas, A William Barrette, Papillary and Verrucous lesions of the oral mucosa are classified into:⁵

I. Benign

- Viral papillomas:
 - Squamous papilloma
 - Verruca vulgaris
 - Condyloma acuminatum
 - Focal epithelial hyperplasia
- Reactive Verrucous and papilla-nodular lesions:
 - Fibro-epithelial polyps
 - Verruciform xanthoma

- Papillary hyperplasia
 - Pyostomatitis vegetans
 - Sialadenoma papilliferum
 - Acanthosis nigricans
 - Darier's disease
- II. Potentially Malignant:
- Verrucous hyperplasia
 - Papillary dysplasia
 - Proliferative (verrucous) leukoplakia
- III. Malignant:
- Verrucous carcinoma
 - Papillary carcinoma:
 - Non-invasive (synonymous with papillary dysplasia)
 - Invasive (essentially a conventional squamous cell carcinoma requiring treatment as such)
 - Carcinoma cuniculatum (essentially a conventional, well differentiated squamous cell carcinoma requiring treatment as such)

(C) According to Eversole LR, Papillary, papular, and multiple polypoid lesions are classified into:⁶

1. Focal Papillary lesions
 - Squamous papilloma
 - Verruca vulgaris
 - Condyloma acuminatum
 - Verruciform xanthoma
 - Sialadenoma papilliferum
 - Giant cell Fibroma
2. Focal and Umbilicated papules
 - Keratoacanthoma
 - Warty dyskeratoma
 - Molluscum contagiosum
3. Diffuse and multifocal papillary lesions
 - Condyloma Acuminatum
 - Focal dermal Hypoplasia
 - Nevus unius Lateris
 - Oral florid papillomatosis
 - Verrucous leukoplakia
 - Verrucous carcinoma
4. Diffuse Papular and Polypoid lesions
 - Papillary hyperplasia
 - Keratosis follicularis
 - Focal epithelial hyperplasia
 - Pyostomatitis Vegetans
 - Crohn's disease

DIAGNOSIS OF VERRUCOUS-PAPILLARY LESIONS

Usually clinical appearance and characteristic histopathologic features are useful for the diagnosis of verrucous papillary lesions. Occasionally, other diagnostic tools are also needed for the definitive diagnosis of few of these entities. Special stains are used for molluscum bodies in molluscum contagiosum are stained by Feulgen staining which demonstrates DNA-containing viral inclusions as Magenta, in Verruciform Xanthoma, acanthotic epithelial process, may assume an unusual orange color in H & E stained slides. In addition, large foamy cells with diastase-resistant, PAS positive granules fill the papillary corium and cytological smears may show presence of koilocytes, especially of PAP smears. Ultrastructural studies such as use of electron microscopy enables visualization of HPV particles in verrucous lesions associated by HPV. These HPV viral particles appear in scattered form within the nuclei of the affected epithelial cells. However, due to its low sensitivity, electron microscopy has merely historical diagnostic value.

Furthermore, even if HPV particles are detected, an identification of the specific HPV genotype present is not possible.⁹ Immunohistochemical (IHC) studies are also done as they are found to be most consistent and reproducible traditional method for HPV detection. IHC of papilloma virus structural proteins may confirm the presence particular HPV genotype. However, inconsistency in antigen detection may result from sampling error, and destruction of antigens during tissue processing or lengthy storage.⁹ However, there are recent molecular methods being considered at present as a key tool in the detection of HPV in verrucous-papillary lesions. The molecular methods which enable the detection of viral DNA in tissue morphology content such as In situ hybridization which detects HPV in tissue specimens and those in which tissue destruction is unavoidable for detection of HPV DNA such as Polymerase chain reaction (PCR) which is currently the most sensitive method for HPV detection. However, because of frequent contamination problem, it should be applied in diagnostic settings with great caution.⁹

SUMMARY AND CONCLUSION

The diagnosis of benign, reactive verrucous and

ORAL MANIFESTATIONS AND HISTOPATHOLOGICAL FEATURES OF VERRUCOPAPILLARY LESIONS^{2,4,7,8}

LESIONS	ORAL MANIFESTATIONS	HISTOPATHOLOGICAL FEATURES
Squamous Papilloma	Exophytic lesion with numerous fingerlike surface projections, cauliflowerlike or wartlike appearance, pedunculated	Finger like projections of epithelium with fibrovascular core, acanthosis, kiliocytes,
Verruca Vulgaris	Papule or nodule with papillary projections or rough pebbly surface, pointed narrow stalk	Finger like projections of epithelium with connective tissue core, reteridges converging - Cupping effects, prominent granular cell layer, kiliocytes
Inflammatory Papillary Hyperplasia	Erythematous or edematous papillary projections - Cobble stone appearance, focal telangiectatic sites	Para/Orthokeratosis, central core of connective tissue, pseudo-epitheliomatous hyperplasia, severe inflammatory cell infiltrate
Condyloma Acuminatum	sessile, pink, well demarcated, nontender exophytic mass with short, blunt surface projections giving it a "Raspberry or Mulberry" appearance.	Parakeratotic papillary surface projections, keratin filled crypts between prominences, acanthosis, kiliocytes, vacuolated cells
Condyloma Latum	soft red, often mushroom like mass with a generally smooth lobulated surface	Acanthosis, intra/intercellular edema, transmigration of neutrophils, perivascular plasma cell infiltrate
Heck's Disease/ Focal Epithelial Hyperplasia	Soft, nontender, flattened or rounded papules, broad based, sessile with multiple clustered plaques	Focal acanthosis, lack of connective tissue core, reteridges widened - club shaped, presence of mitosoid cells
Molluscum Contagiosum	Hemispheric lesions with central umbilication, single or multiple discrete elevated nodules	Thickening and downgrowth of epithelium, presence of molluscum bodies
Fibroepithelial Polyps	Small, round, pink, red or white knob-like growth, pedunculated	Sessile or pedunculated lesion with seborrheic keratosis like hyperplasia of epidermis, increased vascularity
Acanthosis Nigrans	Hypertrophy of filiform papillae - shaggy, papillomatous surface	Basket-weave hyperkeratosis papillomatosis, irregular acanthosis, fused reteridges, dermal papillae-finger like projections filled with keratotic material, pseudohorn cysts
Focal Dermal Hypoplasia	Focal absence of dermis with herniation of subcutaneous fat, multiple papillomas	Fibrovascular stalk composed of loose connective tissue with dilated vessels
Nevus Unius Lateris	Pebbly papillary pattern	Acanthosis, hyperkeratosis, papillomatosis, elongated rete ridges, parakeratotic columns, hyperpigmentation in basal layer

Table 2. Reactive/Infectious Lesions

LESIONS	ORAL MANIFESTATIONS	HISTOPATHOLOGICAL FEATURES
Keratoacanthoma	Firm, non-tender, well demarcated, sessile dome shaped nodule with central keratin plug	Ortho/parakeratin formation, hyperplastic acanthotic epithelium, central keratin plug with an overhanging marginal buttress of epithelium, chronic inflammatory cell infiltrate
Giant Cell Fibroma	Sessile or pedunculated nodule with a lobulated or somewhat papillary surface	Surface epithelium is thin, corrugated and atrophic, with narrow and elongated rete ridges, in CT there are large, plump, spindle-shaped and stellate fibroblasts
Proliferative Verrucous Leukoplakia	Solitary flat white keratotic lesion with a grainy or Verrucous surface or transformation from flat into exophytic and wart-like lesions, erythroplakic change	Enhanced acanthosis, basilar hyperplasia, abrupt transition from hyperparakeratosis to hyperorthokeratosis, Civatte bodies are found
Verrucous Hyperplasia	Varying degrees of epithelial dysplasia	Sharp (narrow projections which are heavily keratinized) and Blunt (broader, shorter projections less keratinized or nonkeratinized) variants are found, blunt rete ridges
Verrucous Carcinoma	Exophytic slow growth producing cauliflower like warty lesion which is locally aggressive and well circumscribed	Epithelial proliferation with downgrowth of epithelium into the connective tissue, dysplastic features and parakeratin plugging are seen
Papillary Squamous Cell Carcinoma	Exophytic papillary proliferation but it lacks the prominent surface keratinization	Exophytic proliferation of malignant appearing squamous cells covering the papillae with fibrovascular cores
Carcinoma Cuniculatum	Warty mass like appearance	Keratinizing, endophytic and variably exophytic epithelial mass, with a cohesive rete pattern invaginated into the tissues, microabscess formation
Sialadenoma Papilliferum	Well circumscribed painless, papillary or verrucoid lesion, base of the lesion is board or pedunculated	Exophytic and endophytic proliferation of ductal epithelium, surface has a papillary to verrucoid growth pattern, interpapillary clefts seen, ductal epithelial cells show eosinophilic and oncocytic features

Table 3. Neoplasms and Pre-Malignant Lesions

LESIONS	ORAL MANIFESTATIONS	HISTOPATHOLOGICAL FEATURES
Pyostomatitis Vegetans	Erythematous, edematous, nodular or fissured, areas of ulcerations are formed which later coalesce – snail tract ulcerations	Hyperkeratosis, acanthosis, often with a papillary surface or/with pseudo epitheliomatous hyperplasia, superficial abscesses are seen
Verruciform Xanthoma	Papillary/granular or verrucous with a sessile or pedunculated base, center of the lesion can appear depressed, cup-shaped or crateriform with or without ulceration	Verruciform or papillary surface changes, often with clefts or crypts between the epithelial projections, parakeratin surface layer, elongated rete ridges
Darriers Disease	Small whitish papules, producing an overall cobblestone appearance.	Hyperkeratosis, papillomatosis, acanthosis, benign dyskeratosis is characterized by rather typical cells called corps, ronds and grains
Warty Dyskeratoma	Small whitish area of mucosa with central depression	Central orthokeratin or parakeratin core beneath which the epithelium shows a suprabasilar separation resulting in a cleft like space containing acantholytic and benign dyskeratotic cells

Table 4. Idiopathic/Miscellaneous Lesions

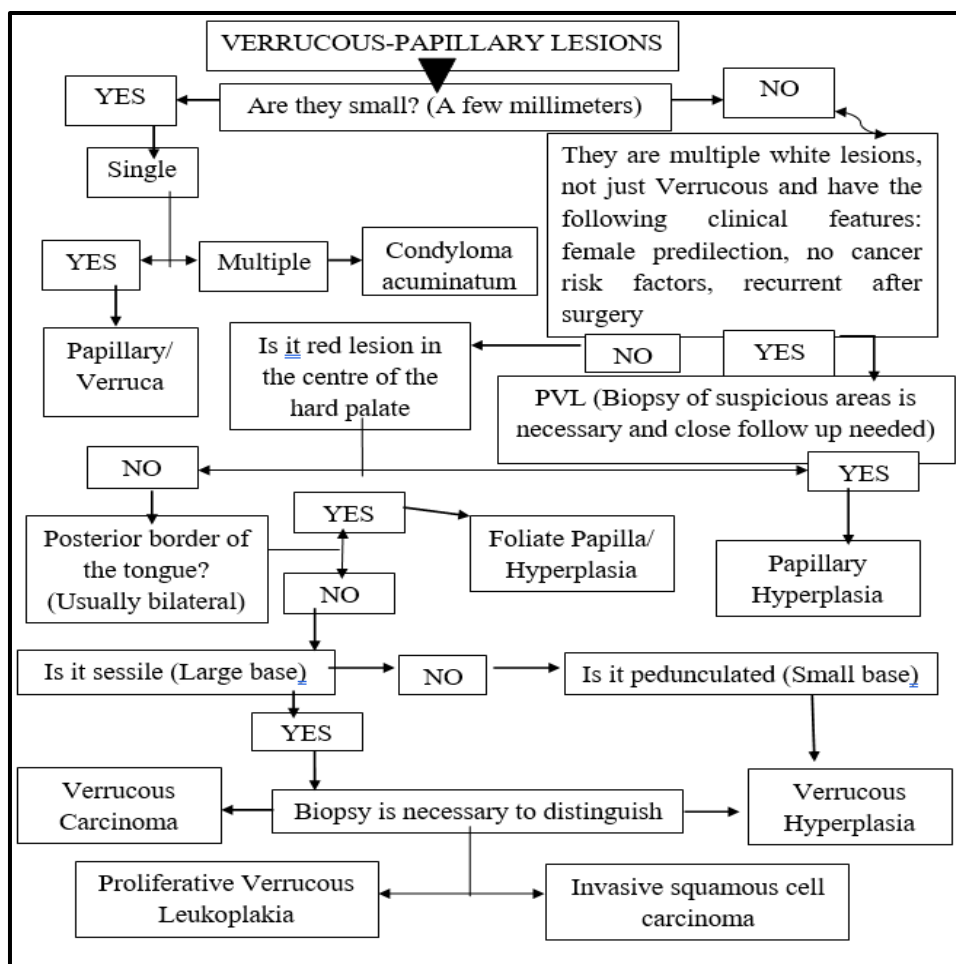


Figure 1. Diagnostic Flowchart of Verrucous-Papillary Lesions of the Oral Cavity

papillary oral lesions usually little difficult, whereas the lesions with their dysplastic counterparts unless the lesion is at either end of the spectrum of verrucous hyperplasia and verrucous carcinoma can be diagnosed with characteristic histopathological features. HPV is found to be associated with majority of these lesions. HPV effects the oral epithelium causing various proliferative and dysplastic changes in the epithelium. There are few lesions like papillary hyperplasia, verruciform xanthoma, cowden syndrome, nevus unius lateris, acanthosis nigricans which are without known viral association. Many of these lesions have overlapping features both clinically and microscopically, therefore proper examination of the lesion followed by biopsy and in some cases special diagnostic methods are to be done for accurate diagnosis.

REFERENCES

1. Eversole LR. Papillary lesions of the oral cavity: relationship to human papillomaviruses. *Journal of the California Dental Association* 2000; 28: 922-7.
2. Syrjanen S. Oral manifestations of human papillomavirus infections. *Eur J Oral Sci.* 2018; 126(Suppl. 1): 49-66. <https://doi.org/10.1111/eos.12538>
3. Wood NK, Goaz PW. *Differential diagnosis of Oral and Maxillofacial lesions*, 5th edition, 1998. Mosby Inc.
4. Regezi JA, Sciubba JJ, Jordan RCK. *Oral Pathology clinical pathological correlations*. 5th edition. Saunders 2008.
5. Thomas GJ, Barrett AW. *Papillary and Verrucous lesions of the oral mucosa Diagnostic Histopathology* 2009;15: 279-85.
6. Eversole LR. *Clinical outline of oral pathology*:

Diagnosis and treatment, 3rd edition. 1992. Lea & Febiger, Philadelphia.

7. Rajendran R, Sivapathasundharam B. Shafer's text book of oral pathology. 8th edition. New Delhi: Elsevier; 2016

8. Neville BW, Damm DD, Allen CM, Bouquot JE. Oral & maxillofacial pathology. 1st South India Edition. New

Delhi: Elsevier; 2015.

9. Thompson LDR. Head and neck pathology a volume in series foundations in Diagnostic pathology. Churchill Livingstone, 2006: 34-6.

10. Gandolfo S, Scully C, Carrozzo M. Oral Medicine. Churchill Livingstone Elsevier, 2006: 32-3.

Cite this article as:

Khaled S, Bharadwaj SR, Anjum B, Satyanarayana D. Verrucopapillary Lesions of the Oral Cavity: A Review. *Int Healthc Res J.* 2020;4(7):RV1-RV7. <https://doi.org/10.26440/IHRJ/0407.10365>

Source of support: Nil, **Conflict of interest:** None declared

AUTHOR AFFILIATIONS: (*Corresponding Author)

1. Assistant Professor, Master of Dental Surgery, Department of Oral and Maxillofacial Pathology, Sri Balaji Dental College, Hyderabad, Telangana
2. Assistant Professor, Master of Dental Surgery, Department of Orthodontics and Dentofacial Orthopedics, HKES, Nijalingappa Institute of Dental Sciences, Gulbarga, Karnataka
3. Assistant Professor, Master of Dental Surgery, Department of Oral and Maxillofacial Pathology, Panineeya Institute of Dental Sciences & RC Hyderabad, Telangana
4. Associate Professor, Master of Dental Surgery, Department of Public Health Dentistry, Panineeya Institute of Dental Sciences & RC Hyderabad, Telangana

Contact corresponding author at: satya.gullu[at]gmail[dot]com